

PATIENT REPORT

PATIENT INFORMATION

PATIENT, TEST

DOB/Age: 3/30/1963 (Age: 57)
Sex: F
Phone #: 555-222-4433
MRN #:

PHYSICIAN INFORMATION

ROBERT PARKER, DDS
3179 MAIN ST.
ANYTOWN, MA 55564

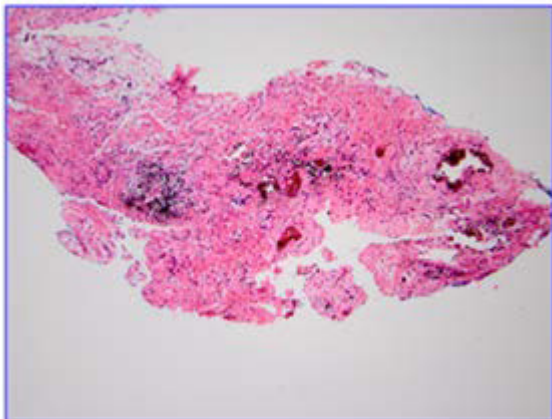
One Cranberry Hill - Suite 303
Lexington, MA 02421
800-325-7284
617-252-6563 Fax
Medical Director: Lisa Cohen, M.D.

SPECIMEN INFORMATION

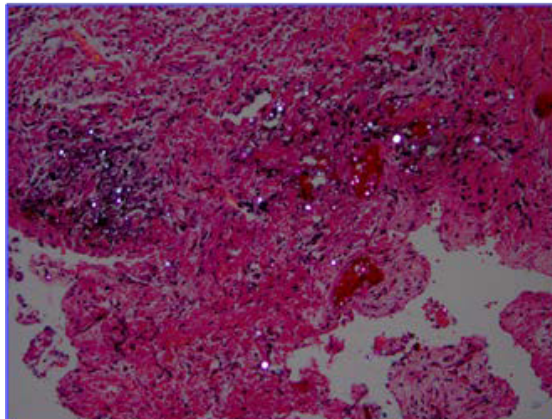
Procedure Date: 3/11/2020
Received Date: 3/12/2020
Date of Report: 3/13/2020

Accession #: **TST16-56970** Primary
Pathologist: **SOOK-BIN WOO, D.M.D.**

IMAGES



periapical scar



refractile AH Plus sealant

Images are for illustrative purposes only and should not be used as diagnostic tools.

DIAGNOSIS

SOFT TISSUE, APEX OF #5, APICOECTOMY:

- PERIAPICAL SCAR WITH CHRONIC INFLAMMATION AND ROOT CANAL FILLER (AH PLUS) [522.6].

Clinical Impression

Periapical granuloma?

Clinical Data

Root canal sealer extruded, missed anatomy, periapical lesion confined to the apex of # 5.

Microscopic Description

The section consists of densely collagenized fibrous scar tissue with a moderate chronic inflammatory infiltrate. A few small vessels are noted. There are many round crystalline refractile foreign material surrounded by a brightly eosinophilic material typical for AH Plus root canal sealant.

Gross Description:

Received in formalin labeled "apical" are two irregular fragments of tan tissue measuring 0.2 x 0.2 x 0.2 and 0.3 x 0.2 x 2.2 cm. The specimen is entirely submitted in cassette 1.

All cases processed after 08/03/2009 use a barcode identifier unique to this patient to ensure specimen integrity.

The technical and gross preparation of this specimen was performed at Strata Pathology Services Inc., One Cranberry Hill, Lexington, MA 02421 – Medical Director: Beatriz Tapia-Centola, M.D.

REK/LC/jb/1/26/2017