

Minnie Tie Maxillomandibular Fixation: A Case Report of use in a Bilateral Temporomandibular Joint Replacement Surgery

Jenzer AC*, Ivory JW, Czerepak JL and Austin TJ

Department of Oral and Maxillofacial Surgery, Eisenhower Army Medical Center, Fort Gordon, USA

*Corresponding author: Jenzer AC, Staff Surgeon, Residency, Department of Oral and Maxillofacial Surgery, Eisenhower Army Medical Center, Fort Gordon, GA, 30905, USA; Tel: +1-706-787-2648; E-mail: Andrew.c.jenzer.mil@mail.mil

Received date: 07 December 2020; Accepted date: 12 December 2020; Published date: 18 December 2020

Citation: Jenzer AC, Ivory JW, Czerepak JL, Austin TJ (2020). Minnie Tie Maxillomandibular Fixation: A Case Report of use in a Bilateral Temporomandibular Joint Replacement Surgery. SunText Rev Dental Sci 1(4): 123.

Copyright: © 2020 Jenzer AC, et al. This is an open-access article distributed under the terms of the Creative Commons Attribution License, which permits unrestricted use, distribution, and reproduction in any medium, provided the original author and source are credited.

Abstract

A 60-year-old female diagnosed with bilateral temporomandibular joint Wilkes Class 5 fibrous ankyloses underwent custom total joint replacements. The operative team utilized Minnie Ties Agile Maxillomandibular (MMF)™ fixation for the parts of the surgery that required MMF. Minnie Ties function essentially as oral zip ties, made of a strong, braided polyester structure with a self-locking clasp and a blunt metal introducer tip. This technique was fast, easy, and produced an excellent result by providing MMF when needed and post-operatively maintaining the same occlusion.

Keywords: Maxillomandibular fixation; Temporomandibular joint surgery; Maxillomandibular fixation techniques

Case Report

A 60-year-old female was evaluated in late 2019 with a chief complaint of difficulty with mouth opening for over ten years. She had a history of past temporomandibular joint surgeries with the last being bilateral discectomies done in 1999. Her past medical history was positive for psoriatic arthritis, hypothyroidism, gastroesophageal reflux, and seasonal allergies. Her maximal incisal opening was 22mm with a hard stop, with minimal pain during function. She was staged as a Wilkes Class 5 with fibrous ankyloses and offered bilateral custom total joint replacements to which she agreed.

The patient was brought to the operating room where the authors performed the aforementioned procedure using retromandibular (Figure 1) and endaural (Figure 2) approaches bilaterally. The case proceeded normal and without incident. During the procedure, the operating team put the patient into maxillomandibular (MMF) fixation twice. First, the team completed both approaches with condylar resection placement of the custom fossae with two screws each (Figures 3 and 4). The patient was then placed into MMF and the custom condylar

portions were placed and also secured with two screws each. MMF was released, the occlusion was verified, and the patient placed back into MMF for the placement of the rest of the screws, placement of harvested abdominal fat, and closing of the incisions.

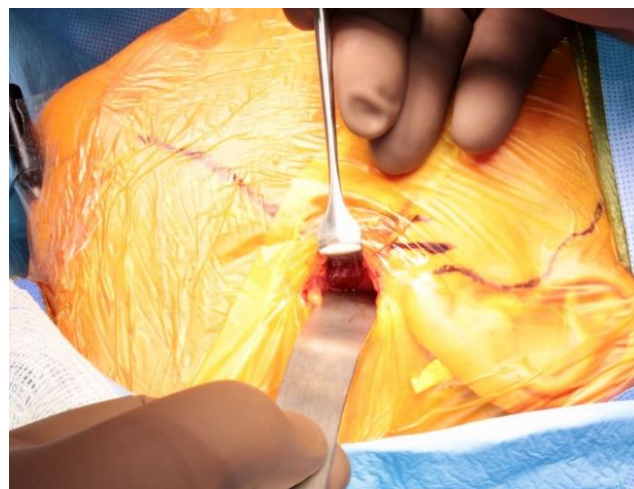


Figure 1: Retromandibular approach on the left side.

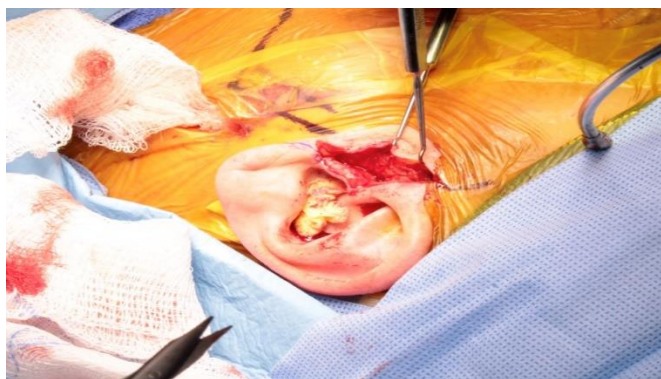

Figure 2: Endaural approach on the left side.

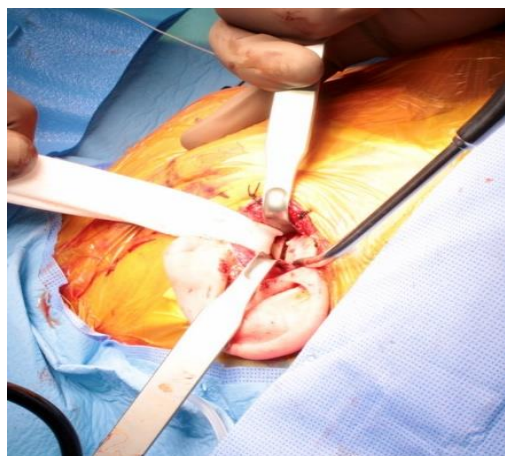


Figure 3: Left temporomandibular joint exposed. Condylar head cut using a piezo ultrasonic technique.

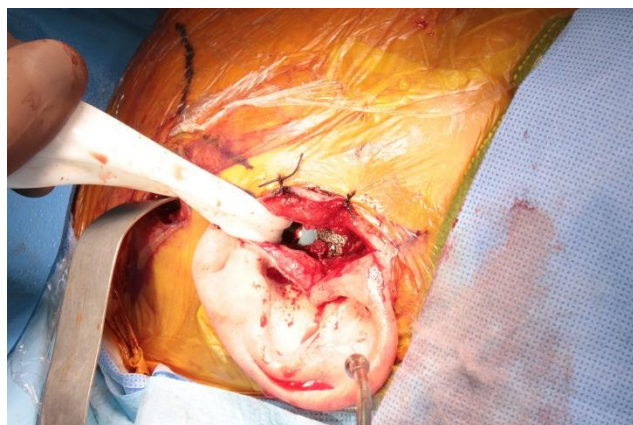
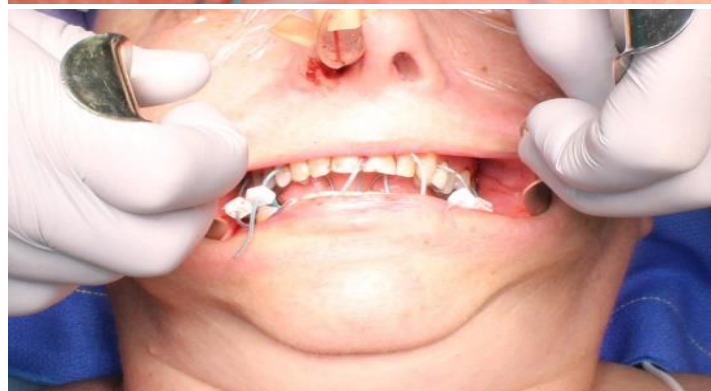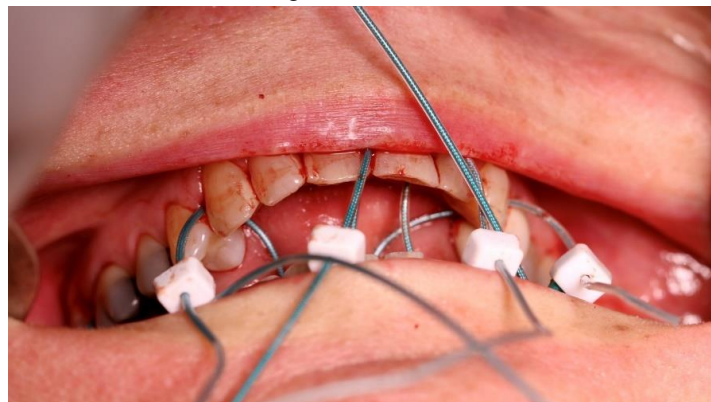


Figure 4: Condylar head removed, custom fossa inserted and secured using two screws.

To accomplish these two phases of MMF, the surgical team used Minnie Ties Agile MMF™, a self-locking suture that resembles a zip tie, made by Invisian Medical, with FDA approval in 2017. Minnie Ties are made of a braided polyester structure with a bonded polypropylene coating, have a blunt metal introducer tip, and a single self-locking clasp. The concept is to use them in the same manner as inter-dental wiring, simply pass them through a

maxillary contact and a mandibular contact and tighten. The idea is to propose another method of MMF besides arch bards, hybrid devices, inter-dental wiring, and MMF screws.



Figures 5 and 6: Six Minnie Ties placed at the start of the case prior to prepping and draping, left loose to allow manipulation of the mandible.

After intubation but prior to prepping the patient, the surgical team placed six total Minnie Ties and left them loose (Figures 5 and 6). This took the surgical team approximately ten minutes to complete. The patient was then prepped and draped and case proceeded as described above. Upon completion of condylar resection and placement of custom fossae, the surgical sites were packed, covered with antimicrobial Ioban™, tegoderm, and the mouth towed and draped off to prevent contamination. While part of the surgical team remained sterile, the other part went to the mouth and tightened down the Minnie Ties, efficiently securing the patient into her pre-operative occlusion (Figure 7). This took the team also less than ten minutes to complete. After removing the dirty drapes and re-securing of the oral cavity, the custom condylar portions were placed with two screws each and the process repeated as above transitioning back to the oral cavity. The Minnie Ties were cut, occlusion verified, and then re-applied with six more Minnie Ties and MMF re-secured. The process was repeated to get back to a sterile field, and the case proceeded as previously described with the Minnie Ties cut out prior to extubation.

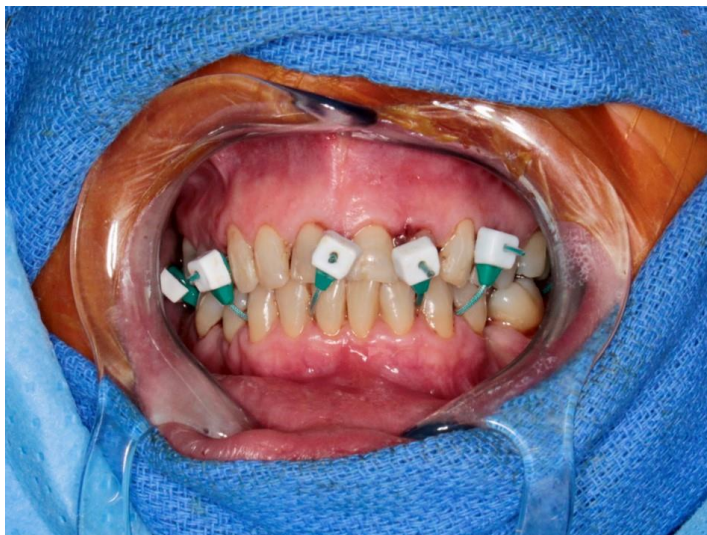

Figure 7: Patient placed into MMF by tightening the Minnie Ties.

The patient's recovery was uneventful and she was discharged 24 hours later with close clinic follow up (Figure 8). Her occlusion remained in the pre-operative position without perceptible change from both the surgeon and the patient's perspective.

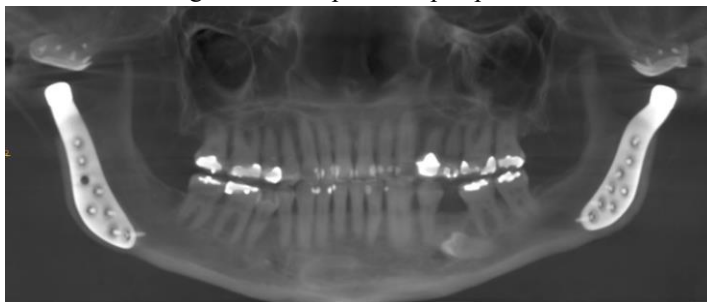

Figure 8: Post-operative reconstructed panoramic image showing custom joints in place and demonstrating occlusion in the planned, pre-operative position with no changes.

Discussion

MMF is an inherent part of oral and maxillofacial surgery as well as many surgeries involving the gnathic bones and/or oral cavity. There are multiple modalities including the traditional Erich arch bars, hybrid devices, MMF screws, Ivy Loops, and inter-dental wiring. Minnie Ties represent another tool for MMF with some advantages and disadvantages. Overall, in the right situation, they offer a quick and easy alternative to the above methods.

Hospitals revolve around the nexus of the operating room generating 60-70% of annual revenue [1]. Operating room (OR) time is a precious commodity with a frequently quoted value of \$60 dollars per minute (and a range of \$22 to \$133), with consideration to multiple variables including staff, type of case, and fixed overhead costs [2-4]. Reducing OR time from a surgeon's perspective will reduce cost, increase throughput of cases, and decrease patients time under anesthesia.

In 1943 John B. Erich described the use of arch bars in his textbook *Traumatic Injuries of Facial Bones (An Atlas of Treatment)*, and popularized the technique. Arch bars are a versatile and classic technique with particular applicability in comminuted gnathic fractures, when there function as a superior tension band is needed, and when one needs the ability for controlling post-operative MMF and/or guiding elastics. Their base as a tooth-borne device allows some control over dentition. Some disadvantages include risk of surgeon injury from wires, post-operative discomfort, and gingival trauma along with hygiene issues. Application time is generally between 30 and 60 minutes with a variability in the literature [5,6]. When adding residents into the mix, this time can fluctuate greatly.

The techniques of hybrid devices, inter-dental wiring, and MMF screws offer fast, bone borne options. Advantages include ease of placement, theoretical reduced risk of surgeon injury, and faster times when compared to arch bars [6-9]. These options are not without their own set of problems, namely damage to odontogenic structures. When one considers again the resident variable, in this author's experience, those risks increase.

Minnie Ties offer another option for MMF. A blunt metal tip is passed between teeth on the maxilla and mandible, passed through a self-locking clasp, and pulled taut. Ideal situations for use include cases where intra-operative MMF is indicated but post-operative is not, such as simple mandible fractures and temporomandibular joint replacement surgeries. The patient should have a stable and reproducible occlusion, with a significant portion of the dentition intact. The Minnie Ties can be configured in multiple ways besides a simple loop, for example, forming an X around four teeth.

In these author's experience, using the Minnie Tie system was quick and efficient. It is not ideal for every situation, but does represent a fast and wireless technique. The author's plan on continuing use of this technique, especially for temporomandibular joint replacement cases.

Disclaimer

The views expressed herein are those of the authors and do not reflect the official policy of the Department of the Army, Department of Defense, or the U.S. government.

Disclosure

None of the authors reported any disclosures.

References

1. Healey T, El-Othmani MM, Healey J, Peterson TC, Saleh KJ. Improving operating room efficiency, part 1: general managerial and preoperative strategies. *J Bone Jt Surg Rev.* 2015; 3: 1-10.



SUNTEXT REVIEWS

2. Macario A. What does one minute of operating room time cost?. *J Clin Anesth.* 2010; 22: 233-236.
3. Park KW, Dickerson C. Can efficient supply management in the operating room save millions? *Curr Opin Anaesthesiol.* 2009; 22: 242-248.
4. Macario A, Dexter F, Traub RD. Hospital profitability per hour of operating room time can vary among surgeons. *Anesth Analg.* 2001; 93: 669-675.
5. Dimitroulis G. Management of fractured mandibles without the use of maxillomandibular wire fixation. *J Oral Maxillofac Surg.* 2002; 60: 1435.
6. Qureshi AA, Reddy UK, Warad NM, Badal S, Jamadar AA, Qurishi N. Intermaxillary fixation screws versus Erich arch bars in mandibular fractures: a comparative study and review of literature. *Ann Maxillofac Surg.* 2016; 6: 25-30.
7. Engelstad ME, Kelly P. Embrasure wires for intraoperative maxillomandibular fixation are rapid and effective. *J Oral Maxillofac Surg.* 2011; 69: 120-124.
8. Coletti DP, Salama A, Caccamese JF Jr. Application of intermaxillary fixation screws in maxillofacial trauma. *J Oral Maxillofac Surg.* 2007; 65: 1746-1750.
9. Fabbroni G, Aabed S, Mizen K, Starr DG. Transalveolar screws and the incidence of dental damage: A prospective study. *Int J Oral Maxillofac Surg.* 2004; 33: 442-446.